

GRACILIS MUSCLE TRANSPOSITION FOR TRAUMATIC ANAL INCONTINENCE A Case Report

Tomy Lesmana, Iwan Kristian, Sudjatmiko

Department of Surgery, Airlangga University School of Medicine, Dr Soetomo Teaching Hospital, Surabaya

ABSTRACT

Traumatic anal incontinence is relatively uncommon, but this is a devastating condition that can affect individual social life. Successful management of anal incontinence with autologous neo-sphincter from gracilis muscle as described by Pickrell motivate us to perform this procedure for our patient. The objective of this paper was to report management a case of traumatic anal incontinence using gracilis muscle transposition. A young female suffered from traumatic anal incontinence and contracture of left labium mayus due to motorcycle accident. The electromyographic examination revealed partial denervation of anal sphincter complex. We performed gracilis muscle transposition procedure for management of the anal incontinence and subsequent biofeedback exercise. The continence is obtained and the biofeedback examination reveal almost normal. In conclusion, unstimulated gracilis muscle transposition and subsequent post operative biofeedback therapy is an effective procedure for the management of traumatic anal incontinence in young patient.

Keywords: *gracilis muscle transposition, traumatic anal incontinence*

Correspondence: Tomy Lesmana, Department of Surgery, Airlangga University School of Medicine, Dr. Soetomo Teaching Hospital, Jl. Prof. Moestopo 6-8, Surabaya, phone 62-31-5026060

INTRODUCTION

Trauma to the perineum is uncommon, but it carries a risk of anal sphincter complex damages that can lead to fecal incontinence. Most authors agree that sphincteric transection should be anatomically reconstructed as soon as possible, but this procedure often difficult due to complexity of tissue damages and the result is often disappointing for maintain the fecal continence because of the dense scar formed can inhibit sphincteric function (Motson 1985, Burch 2000). Numerous technique have been devised for repairing the sphincter including indirect method using circumanal sling of gracilis muscle. Gracilis muscle transposition was described first by Pickrell in 1952 for the treatment of fecal incontinence (Pickrell et al. 1952). Since then, this technique has been used for many indications and has had varying result (Faucheron et al. 1994). The success in treating traumatic anal incontinence with gracilis muscle transposition was first reported by Morgado Nieves in 1975 (Nieves et al. 1975). In this paper, we report another such case.

CASE REPORT

A 24 year-old female was admitted on September 1, 2005. She had a motorcycle accident 2 weeks before

and was found to have a large perineal wound extending from left buttock to the perineum, left inguinal region, and left thigh, with partial disruption of the left site of anal sphincter complex, rupture of the left labium mayus and four rami pubic fracture. The wound was infected and contaminated by feces. There was no bone exposed seen at the wound, normal pulsation of the left femoral artery and normal neurologic examination of the lower extremity. Digital rectal examination revealed an intact rectal wall but there was loss of anal sphincter tone. Debridement of the wound and left colotransversostomy was performed upon her arrival. Six weeks after the first operation we performed split thickness skin graft of the left buttock taken from the opposite thigh. We send the patient home on October 16, 2005 and nursing the wound at the outpatient department until healing obtained.

The electromyographic examination on November 21, 2006 revealed partial denervation of anal sphincter complex. The patient was trained to do a pelvic floor exercise after then. Electromyographic evaluation performed on July 3, 2007 revealed a normal superior anal sphincter and partial denervation of left and right lateral and posterior anal sphincter. The patient was unable to contract her anal muscle and there was a contracture on the left labium mayus. We decided to perform a right gracilis muscle transposition to treat the

fecal incontinence and release the contracture with multiple Z-plasty.

The operation was performed on December 18, 2006. Because of the colostomy, no special preoperative colonic preparation was necessary. Cefotaxime 1 gram 30 minutes before the operation was given as a prophylactic antibiotic. The patient was placed in the lithotomy position after performed general anesthesia (Figure 1). The perineum, lower abdomen, and both lower extremities were prepared and draped. An incision was made in the medial aspect of the right thigh, and right gracilis muscle was identified. Its long tendon beneath the sartorius muscle was separated from its insertion at medial aspect of tibial tuberosity and mobilized by blunt dissection up to the inguinal region, taking care of the proximal neurovascular pedicle (Figure 2). A multiple Z incision was made on the left contracted labium mayus and another incision was made posterior to the anus (Figure 3). A tunnel was created in the extrasphincteric space with preservation of the anterior and posterior raphe. Another subcutaneous tunnel was made between the multiple Z incision and the proximal incision of the thigh (Figure 4). The free gracilis muscle was passed along this tunnel (Figure 5). The thigh was then adducted, and the gracilis tendon was passed around the anal canal in a clockwise fashion to be sutured to the periosteum of the left ischial tuberosity with non absorbable suture (Figure 6,7,8). A finger was inserted in the anus to ensure that the anal canal was sufficiently tight. The wound was closed without drainage and the contracture of the left labium mayus was released and closed with a transposition flap from the left thigh skin (Figure 9,10). The antibiotic was continued for one day. The patient was discharged from the hospital on the seventh post operative day.

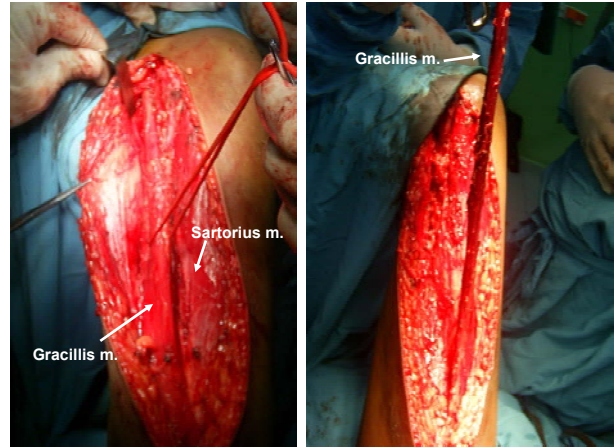


Figure 2. Gracilis muscle is separated from its tibial insertion and mobilized up to inguinal region. Note preservation of the neurovascular pedicle.

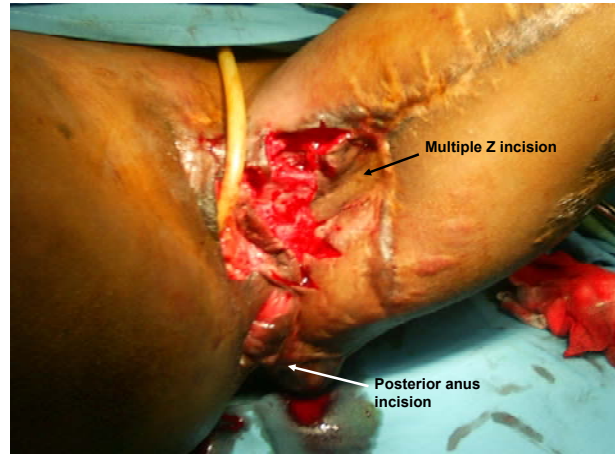


Figure 3. The multiple Z incision and the posterior anus incision.

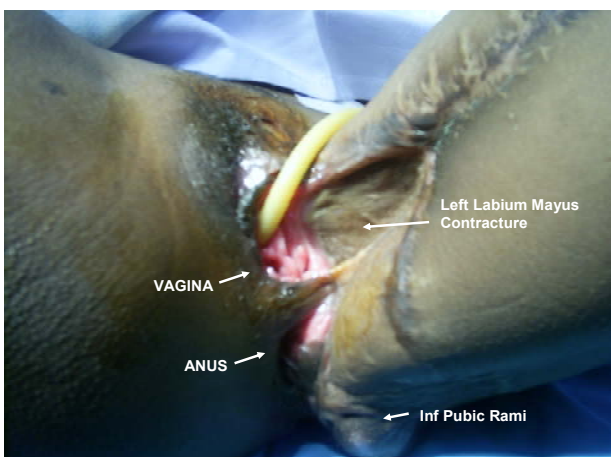


Figure 1. Patient in lithotomy positions showing the condition of the perineum before the operation

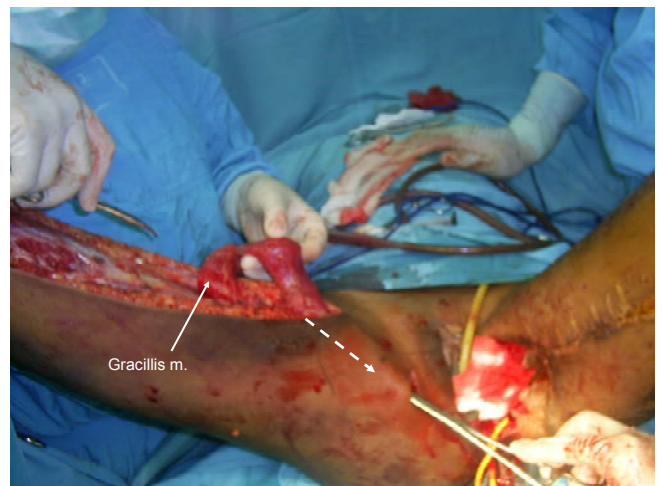


Figure 4. A tunnel made between the multiple Z-plasty incision and the proximal incision of the thigh. Additional incision in between was created to help the passage of the muscle.

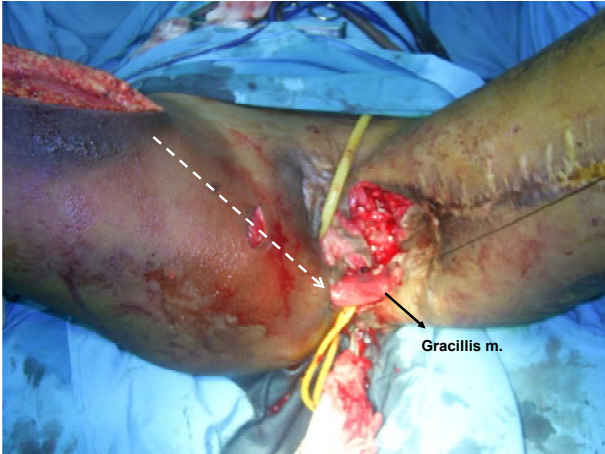

Figure 5. The free gracilis muscle passed along the tunnel.

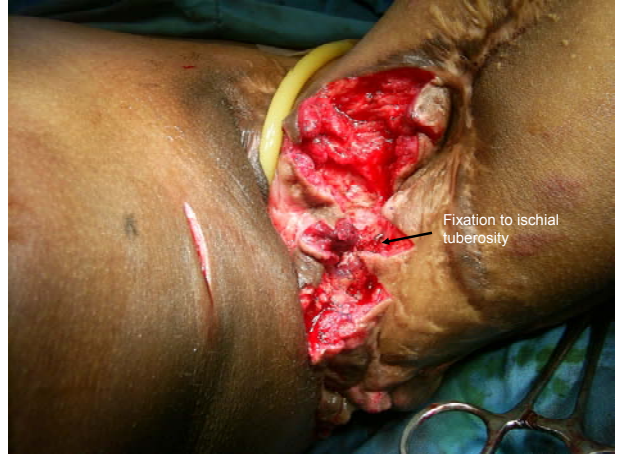

Figure 8. Fixation of the tendon to left ischial tuberosity using non absorbable suture material. Note that the leg must be adducted prior to the fixation.

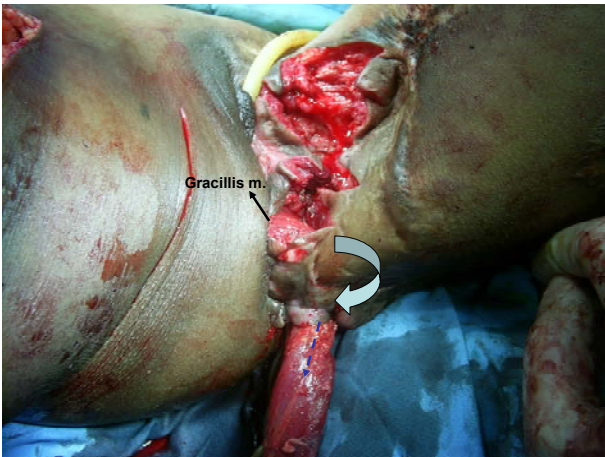


Figure 6. The tendon is pulled trough posterior anal incision clockwise.

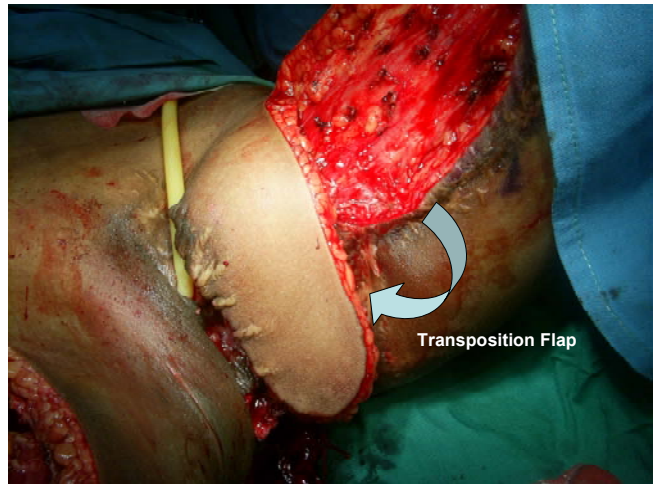


Figure 9. Transposition flap from the left thigh to close the post contracture release defect.

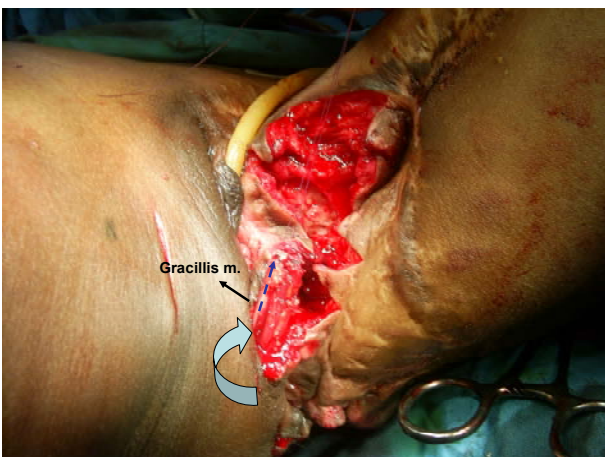


Figure 7. The tendon passes behind gracilis muscle after encircling the anus.

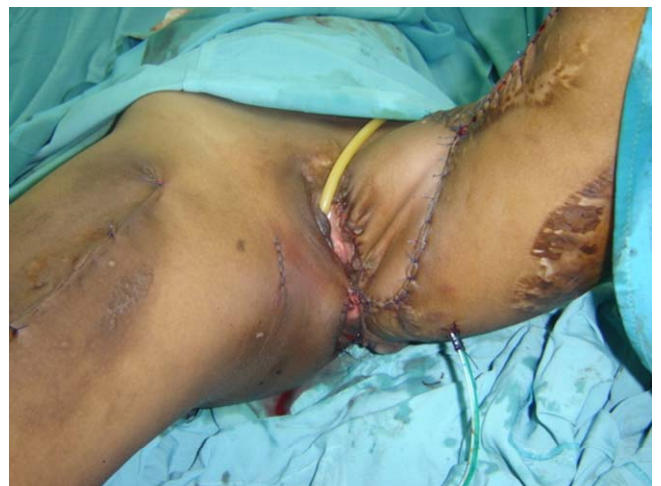

Figure 10. Post operative picture of the perineum.

The patient was trained to do a pelvic floor exercise with biofeedback therapy for six month. Using biofeedback examination (Myomed 932) to measure the contraction of anal sphincter revealed an improvement of the anal continence after the therapy (Figure 11).

Digital rectal examination also showed ability of the patient to contract the new anal sphincter in the abducted position. The colostomy closure performed on Mei 2, 2008.

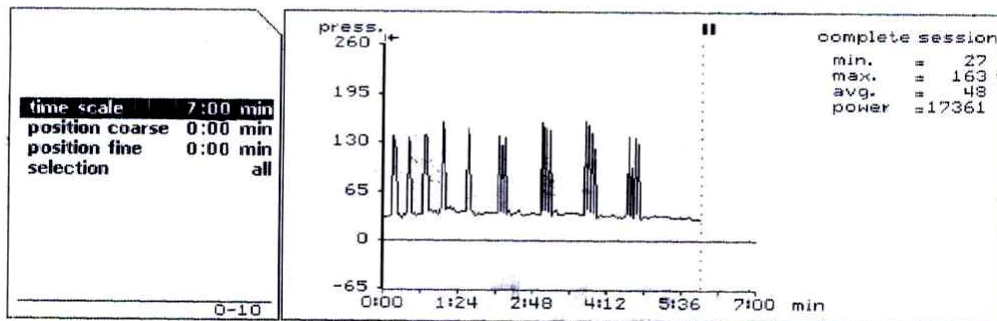


Figure 11. Result after biofeedback therapy.

DISCUSSION

Anal incontinence is defined as either the involuntary passage or inability to control the discharge of fecal material through the anus (Nieves et al. 1975, Muller et al. 2005, Tan et al. 2007). It is a distressing social condition associated with loss of self-esteem and poor personal hygiene (Rao 2004, Kouraklis & Andromanakos 2004, Muller et al. 2005, Andromanakos et al. 2006, Tan et al. 2007). The prevalence ranges between 2.2% and 20.7% (8). There are several causes of anal incontinence including accidental trauma to the perineum that injure the sphincter mechanism (Corman 2005, Andromanakos et al. 2006, Tan et al. 2007).

The evaluation of a patient with anal incontinence involves a detailed clinical assessment together with appropriate physiological and imaging examination of the anorectum (Rao 2004). In the case of accidental trauma, careful physical examination to detect associated injury and identify the injured structure, especially the anal sphincter complex, play role in patient management and further treatment of anal incontinence. An algorithmic approach for evaluation and management of patients with anal incontinence has been proposed by Satish in 2004 (Figure 12). Electromyographic examination is paramount importance in the management of anal incontinence, because the presence of degenerative waves in a large proportion of the anal sphincter complex suggest that direct repair of this complex will probably fail (Nieves et al. 1975, Rudolph & Galandiuk 2002, Barucha 2006). We did not perform anal manometry, anal endosonography, or Pudendal Nerve Terminal Latency (PNTML) because of facility limitation in our hospital. The specific treatment of anal incontinence includes

pharmacologic therapy, biofeedback therapy, anal plugs, and surgical therapy. There are several option for surgical therapy for anal incontinence, one of them is gracilis muscle transposition (Rao 2004, Tan et al. 2007).

Gracilis muscle transposition seems to be most efficacious for those individuals who have suffered sphincter loss from trauma.. It is an alternative surgical approach in the management of anal incontinence when direct repair of the anal sphincter is unsuccessful or when such an effort is considered futile (Corman 1985). The procedure will not result in normal control of defecation because the striated muscle is unable to maintain contraction for a prolonged period of time, but acceptable fecal control may be obtained (Christiansen et al. 1980). Biofeedback examination of our patient reveal resting anal pressure 27 cmH₂O, maximum squeeze pressure 163 cmH₂O, and median squeeze pressure 48 cmH₂O. This result comparable with another previous studies (Christiansen et al 1980, Eccersley 1998).

Gracilis muscle is the most superficial muscle on the posteromedial aspect of the thigh in the adductor group of muscle. It broad and fairly flat proximally, arises from anterior margins of the lower half of the pubic symphysis and the upper half of the pubic arch. It becomes thinner distally, ends in a rounded tendon which passes behind the medial condyle of the femur, then curves around the medial condyle of the tibia where it inserts medial the medial surface of tibia body below the condyle. It functions to adduct the thigh, flexes the thigh and rotates it inward. The nerve supply is derived from the obturator which enters the proximal third of the muscle. Its principal blood supply is from

profunda femoris vessel, enters the muscle along with the nerve in the neurovascular bundle. Because of the location, the long tendinous distal part, and the high level of neurovascular bundle, the gracilis muscle become an ideal autologous neosphincter because it can be mobilized and the tendon can reach the contralateral ischial tuberosity after encircling the anal canal without endangering its vitality or function (Pickrell et al. 1952, Nieves et al. 1975, McGregor 2005).

The ability of gracilis muscle transposition to maintain anal continence influenced by technical detail in adduction of the leg before suturing the gracilis tendon to the ischial tuberosity, the absence of post operative sepsis, absence of intense and circumferential anoperineal fibrosis and the postoperative training under professional surveillance (Corman & Keighley 1979,

Corman 1985, Yoshioka et al. 1988, Faucheron et al. 1994, Sielezneff 1996). We did adducted the right thigh of our patient before fixation of the gracilis muscle, there was no post operative sepsis, the fibrosis only affect half of the anoperineal circumferential, and she had been trained with biofeedback exercise. In this case colostomy played an important role in protecting the perineal wounds against post operative infection.

The newer technique Dynamic Gracilloplasty described by Beaten et al in 1988 overcome the problem of inability of gracilis muscle to maintain the contraction for a long time. Because the expensiveness of the procedure and the comparable result between unstimulated and stimulated graciloplasty in younger patients, we don't performed electrical stimulation for this patient (Eccersler et al. 1998).

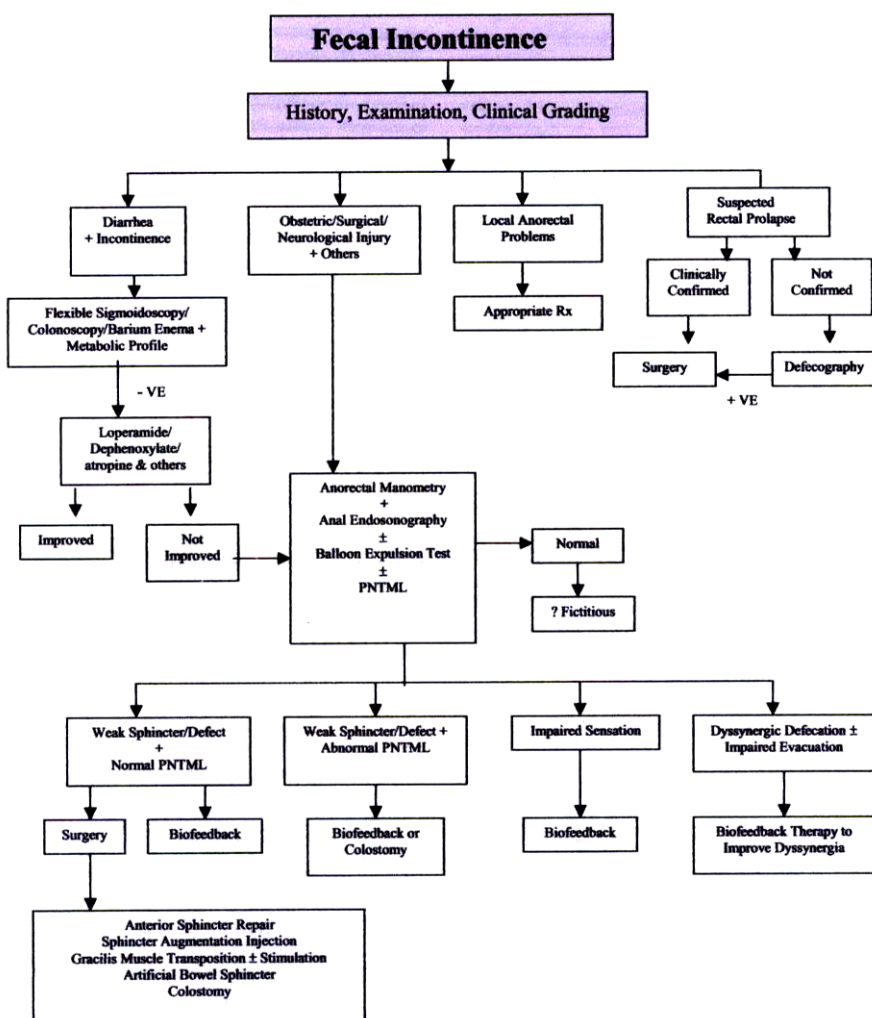


Figure 12. Algorithm approach for the evaluation and management of patients with anal incontinence. PNTML: Pudendal Nerve Terminal Latency. (From Rao SSC. Practice Guidelines: Diagnosis and management of fecal incontinence. American Journal of Gastroenterology 2004)

CONCLUSIONS

We report a case of traumatic anal incontinence successfully treated by gracilis muscle transposition using the technique described by Pickrell. We believe that even without electrical stimulation, this technique is an effective procedure for the management of traumatic anal incontinence especially in young patient. The application of temporary colostomy before the procedure, meticulous surgical technique, together with good post operative exercise is the key of successful management of this case.

REFERENCES

- Andromanakos, N, Filippou, D, Skandalakis, P, Papadopoulos, V, Rizos, S, & Simopoulos, K 2006, 'Anorectal incontinence: pathogenesis and choice of treatment', *J Gastrointest Liver Dis* vol. 15, pp. 41-49.
- Bharucha, AE 2006, 'Update of tests of colon and rectal structure and function', *J Clin Gastroenterol*, vol. 40, pp. 96-103.
- Burch, JM 2000, 'Injury to the colon and rectum', in Mattox KL, Feliciano DV, & Moore EE (eds), *Trauma*, 4th edn, McGraw-Hill, New York, pp. 763-782.
- Christiansen, J, Sorensen, M, & Rasmussen, OM 1980, 'Gracilis muscle transposition for fecal incontinence', *Br J Surg*, vol. 77, pp. 1039-1040.
- Corman, ML 1979, 'Management of fecal incontinence by gracilis muscle transposition', *Dis Col & Rect*, vol. 22, pp. 290-292.
- Corman, ML 1985, 'Gracilis muscle transposition for anal incontinence: late results', *Br J Surg*, vol. 72, pp. 21-22.
- Corman, ML 2005, *Colon & Rectal Surgery*, 5th edn, Lippincott William & Wilkins, Philadelphia, pp. 347-425.
- Eccersley, AJP, Lunniss, PJ, & Williams, NS 1998, 'Unstimulated graciloplasty in traumatic fecal incontinence', *Br J Surg*, vol. 85, pp. 42-43.
- Faucheron, JL, Hannoun, L, Thome, C, & Parc, R 1994, 'Is fecal continence improved by nonstimulated gracilis muscle transposition?', *Dis Colon Rectum* vol. 37, pp. 979-983.
- Kouraklis, G, Andromanakos, N 2004, 'Anorectal incontinence: aetiology, pathophysiology and evaluation', *Acta Chir Belg*, vol. 104, pp. 81-91.
- McGregor, AD 2005, 'Functional reconstruction of the perineum and pelvic floor', in Beynon J, Carr ND (eds), *Progress in Colorectal Surgery*, Springer, London, pp. 154-170.
- Motson, RW 1985, 'Sphincter injuries: indication for, and results of sphincter repair', *Br J Surg*, vol.72, pp. 19-21.
- Muller, C, Belyaev, O, Deska, T, Chromik, A, Weyhe, D, & Uhl, W 2005, 'Fecal incontinence: an up-to-date critical overview of surgical treatment options', *Langenbecks Arc Surg*, vol. 390, pp. 544-552.
- Nieves, PM, Valles, T, Aranguren, G, & Maldonado, D 1975, 'Gracilis muscle transplant for correction of traumatic anal incontinence: repost of a case', *Dis Col & Rect*, vol. 18, pp. 349-354.
- Pickrell, KL, Broadbent, TR, Masters, FW, & Metzger, JT 1952, 'Construction of rectal sphincter and restoration of anal incontinence by transplanting the gracilis muscle', *Ann Surg*, vol. 135, pp. 853-62.
- Rao, SSC 2004, 'Practice guidelines: Diagnosis and management of fecal incontinence', *Am J Gastroenterol*, pp.585-599.
- Rudolph, W, Galandiuk, S 2002, 'A practical guide to the diagnosis and management of fecal incontinence', *Mayo Clin Proc*, vol. 77, pp. 271-275.
- Sielezneff, I, Bauer, S, Bulgare, JC, & Sarles, JC 1996, 'Gracilis muscle transposition in the treatment of faecal incontinence', *Int J Colorect Dis*, vol. 11, pp. 15-18.
- Tan, JJY, Chan, M, & Tjandra, JJ 2007, 'Evolving therapy for fecal incontinence', *Dis ColonRectum*, vol. 50, pp. 1950-1967.
- Yoshioka, K, & Keighley, MRB 1988, 'Clinical and manometric assessment of gracilis muscle transplant for fecal incontinence', *Dis Colon Rectum* vol. 31, pp. 767-769.